

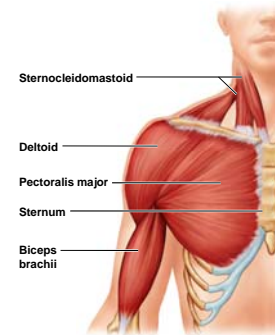
Muscles Crossing the Shoulder Joint

- Deltoid
- Pectoralis major
- Latissimus dorsi
- Supraspinatus
- Infraspinatus
- Teres minor
- Teres major
- Coracobrachialis
- Subscapularis

1

Muscles Crossing the Shoulder Joint

- Deltoid
- Pectoralis major



Muscles Crossing the Shoulder Joint

- **Deltoid**
 - Origin – Acromion, Clavicle
 - Insertion – Deltoid tuberosity of humerus
 - Action – ABduction of arm

2

Muscles Crossing the Shoulder Joint

- **Latissimus Dorsi** – Crosses shoulder
 - Origin – Lower ribs, lumbar vertebrae, iliac crest (all via Thoracolumbar fascia)
 - Insertion – Humerus
 - Action – Extension, ADduction and internal (medial) rotation of humerus

5

Muscles Crossing the Shoulder Joint

- **Pectoralis major** – crosses shoulder joint
 - Origin – Sternum, clavicle
 - Insertion – Greater tubercle of humerus
 - Action - Prime mover of arm flexion, internal (medial) rotation and ADduction of humerus.

3

Muscles Crossing the Shoulder Joint

- **Supraspinatus**
 - Origin – Supraspinatus fossa of scapula
 - Insertion – Greater tubercle of humerus
 - Action – ABduction of humerus

6

Muscles Crossing the Shoulder Joint

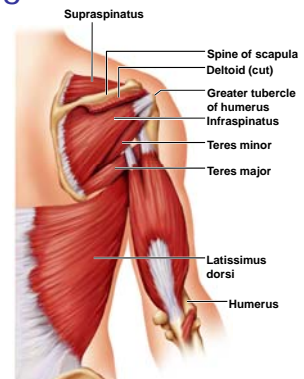
■ Infraspinatus

- Origin – Infraspinatus fossa of scapula
- Insertion – Greater tubercle of humerus
- Action – Lateral (external) rotation of humerus

7

Muscles Crossing the Shoulder Joint

- Latissimus dorsi
- Supraspinatus
- Infraspinatus
- Teres minor
- Teres major



Muscles Crossing the Shoulder Joint

■ Teres minor

- Origin – Lateral boarder of scapula
- Insertion – Greater tubercle of humerus
- Action – Lateral (external) rotation of humerus

8

Muscles Crossing the Shoulder Joint

■ Subscapularis

- Origin – Subscapular fossa of scapula
- Insertion – Lesser tubercle of humerus
- Action –Prime mover: Medially rotates humerus

11

Muscles Crossing the Shoulder Joint

■ Teres major

- Origin – Inferior angle of scapula
- Insertion – Lesser tubercle of humerus
- Action – Extends, medially rotates and ADducts humerus

9

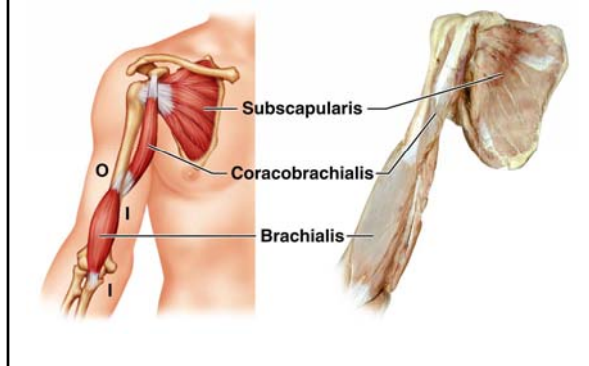
Muscles Crossing the Shoulder Joint

■ Coracobrachialis

- Origin – Coracoid process of scapula
- Insertion – Humerus
- Action – Flexion and ADduction of humerus

12

Muscles Crossing the Shoulder Joint



Muscles Crossing the Elbow Joint

- **Triceps brachii** – Has 3-headed origin
 - Origin – Scapula and humerus
 - Insertion – Olecranon process
 - Action – Extension of forearm

16

Muscles Crossing the Shoulder Joint

- Rotator Cuff Muscles (SITS)
 - Supraspinatus, Infraspinatus, Teres minor, Subscapularis
 - Main muscles that stabilize shoulder
 - An injury to one of these muscles causes shoulder instability
 - All are involved in the throwing motion

14

Muscles Crossing the Elbow Joint

- **Biceps brachii** – Has 2-headed origin
 - Origin – Coracoid process & lip of glenoid cavity
 - Insertion – Radial tuberosity
 - Action – Flexes elbow joint (lifts radius) & supinates forearm

17

Muscles Crossing the Elbow Joint

- Posterior muscles – extensors of the forearm
 - Triceps brachii
- Anterior muscles – flexors of the forearm
 - Biceps brachii – also supinates the forearm
 - Brachialis
 - Brachioradialis

15

Muscles Crossing the Elbow Joint

- **Brachialis**
 - Origin – Humerus
 - Insertion – Coronoid process of ulna
 - Action – Flexes elbow joint (Lifts ulna)

18

Muscles Crossing the Elbow Joint

■ Brachioradialis

- Origin – Humerus
- Insertion – Styloid process of radius
- Action – Forearm flexion

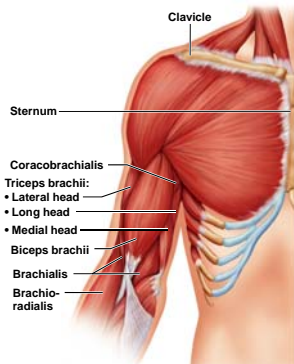
19

Muscles of the Forearm

- Most forearm muscles arise from the distal humerus
- Wrist & fingers are “operated” by muscles in the forearm
- Movements at the wrist include
 - Flexion, extension, abduction, and adduction

22

Muscles Crossing the Elbow Joint



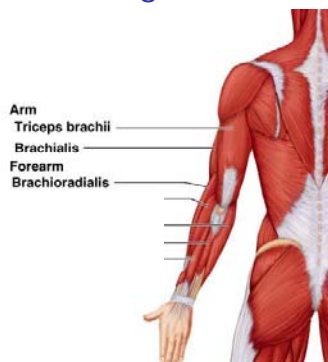
Muscles of the Forearm

■ Flexors

- Anterior flexor compartment
- Originate from a common tendon
 - Medial epicondyle of the humerus

23

Muscles Crossing the Elbow Joint



Superficial Anterior Muscles of the Forearm

■ Pronator Teres

- Origin – Medial epicondyle of humerus
- Insertion – Lateral radius
- Action – Pronates forearm

24

Superficial Anterior Muscles of the Forearm

- **Superficial flexor group** – Flexor carpi radialis, palmaris longus, flexor carpi ulnaris, flexor digitorum superficialis
 - Origin – Medial epicondyle of humerus
 - Insertion – Various points on the hand
 - Action – Wrist and finger flexion

25

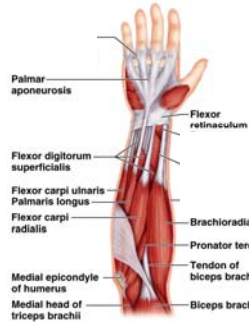Deep Anterior Muscles of the Forearm

- **Flexor digitorum profundus**
 - Origin – Ulna
 - Insertion – Distal phalanges 2-5
 - Action – Flexes distal phalanges 2-5

28

Superficial Anterior Muscles of the Forearm

- Pronator teres
- Superficial flexor group
 - Flexor carpi radialis
 - Palmaris longus
 - Flexor carpi ulnaris
 - Flexor digitorum superficialis



Deep Anterior Muscles of the Forearm

- **Pronator quadratus**
 - Origin – Distal ulna
 - Insertion – Distal radius
 - Action – Pronation of forearm

29

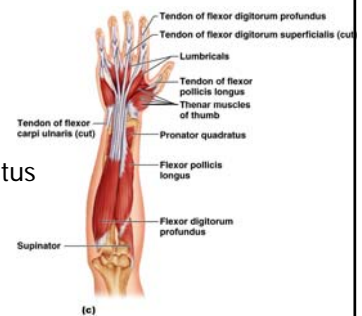
Deep Anterior Muscles of the Forearm

- **Flexor pollicis longus**
 - Origin – Radius
 - Insertion – Distal phalanx of thumb
 - Action – Flexes distal phalanx of thumb

27

Deep Anterior Muscles of the Forearm

- Flexor pollicis longus
- Flexor digitorum profundus
- Pronator quadratus



(c)

Muscles of the Forearm

- **Extensors**
 - Posterior compartment of the forearm
 - Originate at a common tendon
 - Lateral epicondyle of the humerus

31

Deep Posterior Muscles of the Forearm

- **Supinator**
 - Origin – Lateral epicondyle of humerus
 - Insertion – Proximal end of radius
 - Action – Supination of forearm

34

Superficial Posterior Muscles of the Forearm

- **Superficial extensor group of the forearm** - Extensor carpi radialis longus, extensor carpi radialis brevis, extensor digitorum, extensor carpi ulnaris
 - Origin – Lateral epicondyle of humerus
 - Insertion – Metacarpals & phalanges 2-5
 - Action – Extension of wrist and phalanges

32

Deep Posterior Muscles of the Forearm

- **Deep extensor group of the forearm** - Abductor pollicis longus, extensor pollicis brevis and longus, extensor indicis
 - Origin – Radius, ulna and interosseous membrane
 - Insertion – Metacarpals & phalanges of thumb & index
 - Action – Extension of thumb and index finger

35

Superficial Posterior Muscles of the Forearm

- Brachioradialis
- Superficial extensor group of forearm
 - Extensor carpi radialis longus
 - Extensor carpi radialis brevis
 - Extensor digitorum
 - Extensor carpi ulnaris

(a)

Deep Posterior Muscles of the Forearm

- Supinator
- Deep extensor group of the forearm
 - Abductor pollicis longus
 - Extensor pollicis brevis and longus
 - Extensor indicis

(b)